

Restoration of Missing Upper Anterior Teeth using Dental Implant Simultaneous with Bone Grafting- A Case Report

Walid Al-Jallad¹, Shi Bin^{2,*}

¹Department of Prosthodontics, Arab American University-Jenin, Palestine

²Department of Prosthodontics, Hospital of Stomatology, Wuhan City, Hubei Province, PR China.

*Corresponding author: Shi Bin, PhD, DDS, Department of Prosthodontics, Hospital of Stomatology, LuoYu Road 237, Wuhan City, Hubei Province, PR China; Fax: +8602787873260; E-Mail: shibin_dentist@126.com

State Key Laboratory Breeding Base of Basic Science of Stomatology (Hubei-MOST) and Key Laboratory for Oral Biomedicine of Ministry of Education (KLOBM), School and Hospital of Stomatology, Wuhan University, Wuhan, China., prosthodontics

Received Date: August 25, 2014; Accepted Date: September 26, 2014; Published Date: September 29, 2014

Citation: Walid Al-Jallad, *et al.* (2014) Restoration of Missing Upper Anterior Teeth using Dental Implant Simultaneous with Bone Grafting- A Case Report. J Dent Oral Health 1: 1-8

Abstract

Loss of natural teeth could compromise the functional, esthetical and Phonetics demands by patients. Advancement in the oral implant treatment leads to predictable survival rates and create important treatment options available. Evaluating both bone quality and quantity is major requirement in successful osseointegrated dental implant. Bone defect associated with lost teeth in anterior maxilla will affect both surgical placement of implant and subsequent prosthetics rehabilitation. Bone defect correction can be carry on using variety of ways include barrier membrane with guided bone regeneration, block grafts, only grafts or distraction osteogenesis.

This case report is step-by-step procedure in which missing anterior teeth were restored with dental implant and fill the labial defect bone using particulated bone graft and membrane. After initial healing, provisional restoration was used to create esthetical gingival contour around teeth.

Keywords: Anterior maxilla; Esthetics implant restoration; HAP bone graft; Dental implant

Introduction

Teeth may be lost due to many different reasons [1]. Dental caries and periodontal disease count of major causes of loose teeth [2], other causes could contribute in losing teeth in anterior maxilla is trauma, which has a greater anatomical projection and susceptible to this type of injury [3]. Minor trauma cause loss of alveolus and gingiva. Major trauma can cause extensive vertical and horizontal bone loss [4]. Restoration of missing anterior maxillary teeth is challenging due to compromised esthetics associated with missing teeth itself in addition gradual alveolar bone resorption which will further compromise esthetics [5].

Aesthetics and functional demands in the restoring of this particular area have always been a major factor of choosing the treatment option available. In addition; the psychological advantage over the use of partial removable provisional prosthesis [6].

An advent of osseointegration terms (direct structural and functional connection between ordered living bone and the

surface of a load- carrying implant) [7]. Allow rehabilitation of missing anterior teeth using osseointegrated dental implant because of its high predictability.

Endosseous implant success required full coverage of implant surface with bone. Augmentation of local defect of alveolar ridge with bone grafts enable to achieve these prerequisite in insufficient bone volume.

Different surgical procedure available to create enough bone volume such as autogenous bone graft, include only graft, interpositional bone graft, guided bone regeneration and combination of these procedure [8-10].

Estimating the degree of bone defect is not easy since the mucosal contour can mask the actual dimension of the alveolar ridge, ridge mapping, CBCT and Denta Scan can be used.

Case Report

A female patient born in 1973 came to prosthodontics department – Implant center, (Wuhan University dental hospital) complaining of the upper anterior teeth 11, 21, 22 were missing for 3 years (Figure 1).

The following teeth 11, 21, 22 were extracted 3 years ago after car accidents which fracture the crown and leave the roots.

Now she asked for the urgent restoration to improve the function and esthetics.

Conducting a thorough medical history, we found the patient had a good physical condition and denied any systematic diseases or any allergic diseases that were relevant to dental treatment. And she had no mucosal lesions, no bleeding disorder, no tobacco smoking, and alcohol and drug abuse.

Dental history

Questioning the patients reported that teeth 11, 21, and 22 were extracted in another hospital 3 years ago. And since then no any further treatment try to solve the problem due to economical issues.

Clinical Examination

Clinical examination was conducted, and through deep examination of both extra and intra oral examination of reported the following:

Extra-oral: No gross facial asymmetry or swelling was detected. No clicking of TMJ or limitation and deviation of opening.

Intra-oral: Hard tissue examination reveals that Teeth 11, 21, 22 were missing. Evaluation of edentulous space shows that the quantity and quality of edentulous area (alveolar bone) was not good. There were obvious bone defect and labial ridge in form of concavity. (Labial dehiscence) The inter-alveolar spaces were enough for restoration.

Soft tissue examinations show. The thickness of the soft tissue of the edentulous ridge was assessed at different point of the edentulous space and it's about 2 mm measured by a graduated periodontal probe. The color and texture of mucosa was normal.

No obvious mucosal lesions, fibrous connective tissue displacement and other abnormalities were detected.

Periodontal status: Oral hygiene was good. No marginal gingival inflammation was detected. No periodontal pockets were detected. No other tooth mobility was found.

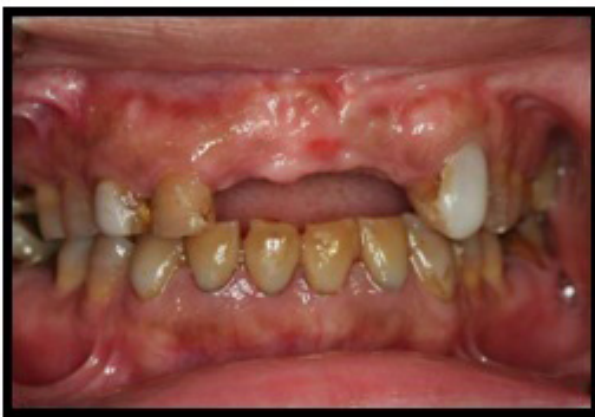

Figure 1: Preoperative labial view

Occlusion: The overbite and over-jet were normal. The occlusion was stable.

Radiographic evaluation showed an excellent condition of the remaining teeth, and there was adequate bone height of

15 mm. the remaining bone was of moderate quality. Alveolar bone had bone defect in missing teeth number 22 (Figure 2). Labial bone dehiscence required bone augmentation in order to achieve long term success [11].

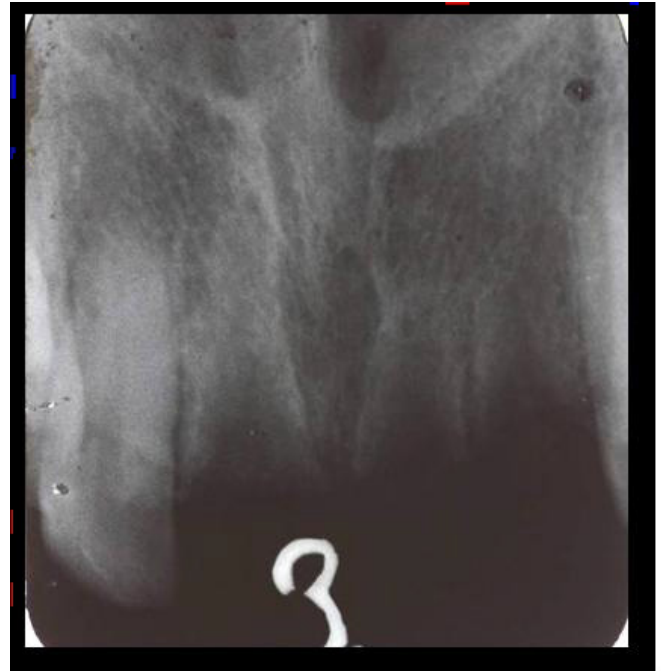

Figure 2: Preoperative peri-apical radiograph

Treatment Option

The treatment options were discuss with patients and where summarized as following , implant supported crown of each missing tooth , or two implant supported bridge, FPD and RPD were presented to the patient, and the time, expenditure, advantages, and disadvantages of each plan were introduced. The patient wanted the best way for restoration, and she didn't care about the time consume. So she chose the implant denture finally.

Details of Treatment

Step 1. Preoperative radiograph examination

Before start implant surgery and as a part of treatment plan process, the patient must have initial radiographic screening. Which is in this case was peri-apical X-ray accomplished by intraoral long cone paralleling technique.

Step 2. Oral hygiene instruction and scaling

The patient understanding of the financial, time, and maintenance requirements was crucial, and these obligations must be made clear to the patient initially and during subsequent appointments. Before the surgery, all the supragingival and subgingival calculus must be removed and blood screening test were performed.

Step 3. Onlay guided bone regeneration

The patient was informed about the common complications of the implant surgery that could happen, and then he signed a consent form. Because of the lack of enough bone, Onlay guided bone regeneration technique was used after implant

placement. Particulated bone and bone graft from the Bone-Trap™ collected during preparation of the implant site along with Bio-Oss granules for covering the implant [9].

Step 4. Surgical procedure

After local anesthesia injection, surgical stent was positioned and supported by adjacent teeth (Figure 3).

A small, sharp-tipped guiding drill was used to create a precise, minimally invasive initial penetration through the mucosa and into bone to locate the exact position of planned implant (Figure 4).

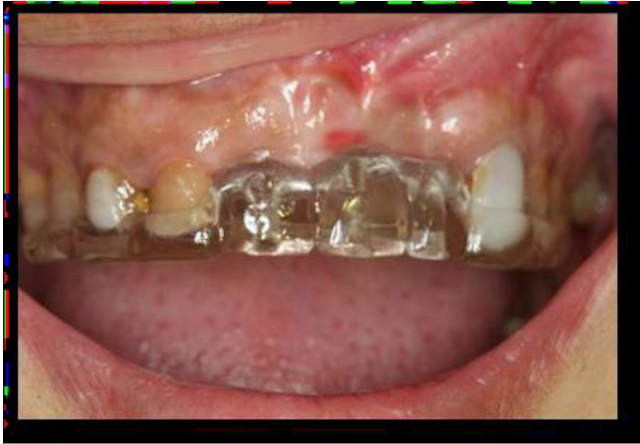

Figure 3: Surgical stent in position

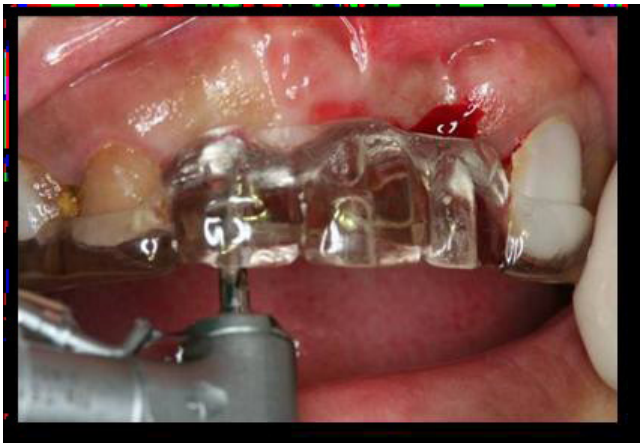

Figure 4: Small, initial penetration through the mucosa and into bone.

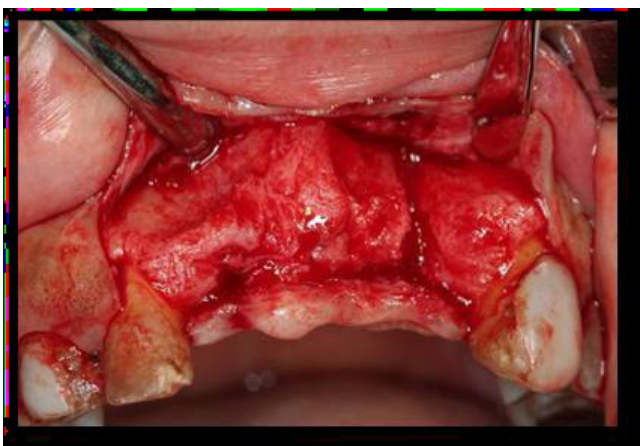


Figure 5: Reflection of full muco-periosteal flap

Then full muco-periosteal flap were reflected exposing the underlying bone (Figure 5). Position the surgical stent and prepare the implant site with correct angulations and depth for implant fixture (Figure 6). A 2mm diameter twist drill was used to drill to the desired depth. The site was 13mm in length. The direction indicator was used to check orientation.

The drill of 3.5mm in diameter was used to open out the cortical bone to the 3.5mm. Then the site was enlarged with the 4.3mm twist drill. Parallel pin was checked in prepared site to evaluate parallelism of prepared implant site for optimal result (Figure 7).

Then screw the site. The Nobel® Replace Select tapered implant (4.3X13mm) and tapered implant (4.3X13mm) were inserted in the site of 11 and 22 respectively initially with an adapter attached to a special contra-angle at slow revolutions, and then by hands using tap wrench and ratchet wrench. The implant was placed with its head just below the crest of the bone, the implant internal triangle tip directed to labial. The insert torque was 45 Ncm (Figures 8&9).

The implant was placed with its head at crest bone level, and then put the healing screw on the abutment connection area. Bio-Oss and collagen membrane filled in spacing. The wound was sutured (Figures 10,11&12). The patient was informed to maintain the oral hygiene. 7-10 days later, she must come back

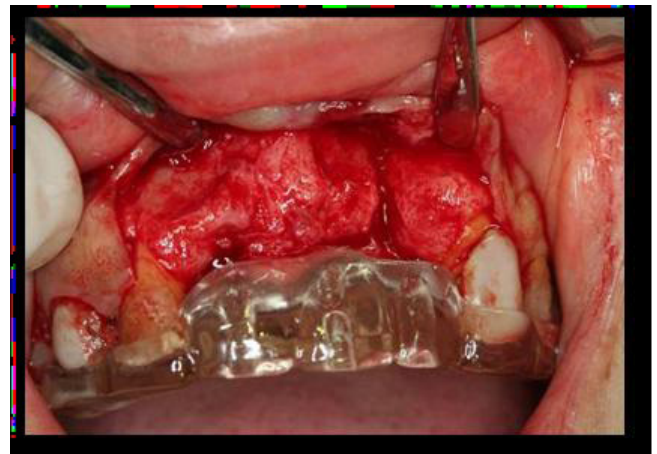

Figure 6: Surgical stent in position after flap reflection (supported by adjacent teeth).

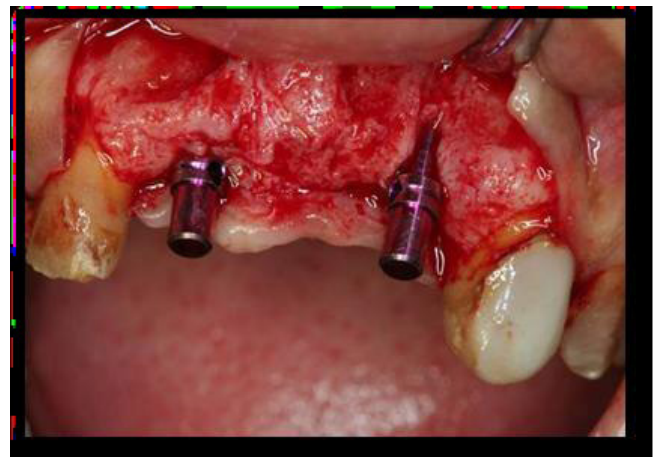


Figure 7: Guide Pin in osteotomy prepared site (check for parallelism and angulations)

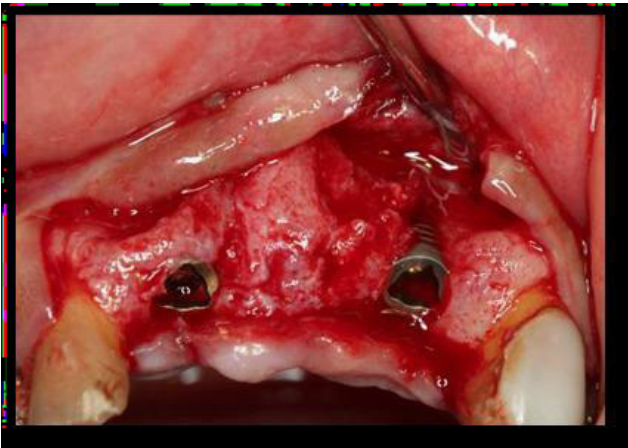


Figure 8: Placement of implant fixture

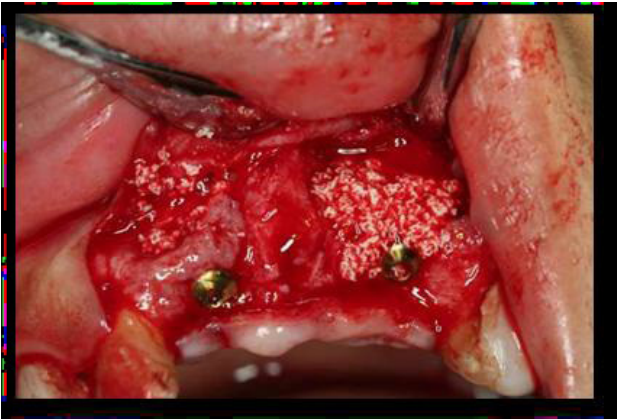


Figure 9: Both Implant fixtures in position

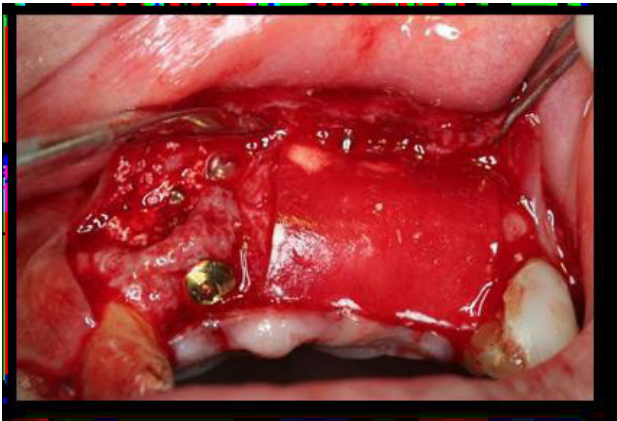


Figure 10: Inlay guided bone regeneration

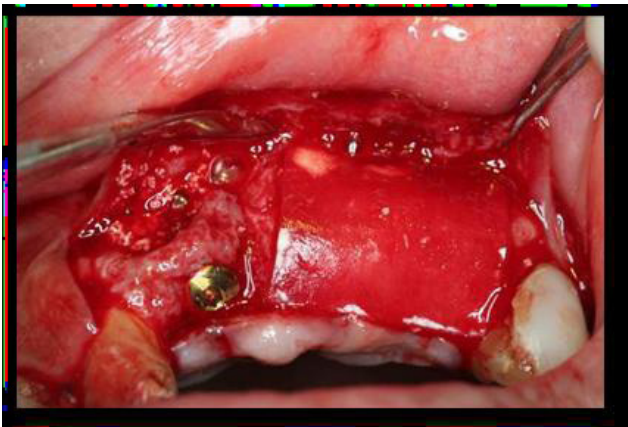


Figure 11: GBR membrane in position

for the removal of the sutures and took a new radiographic for history information (Figure 13).

Step 5. Stage II surgery procedure

After 6 months later, stage II surgery was taken. Providing transmucosal healing abutment for two weeks. The fabrication

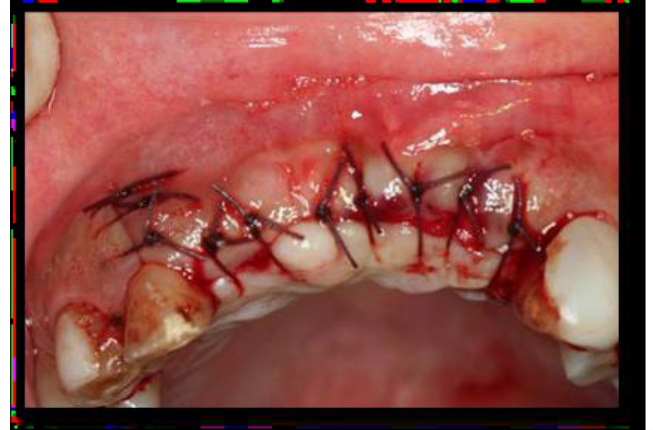

Figure 12: Flap Closer (interrupted suture)

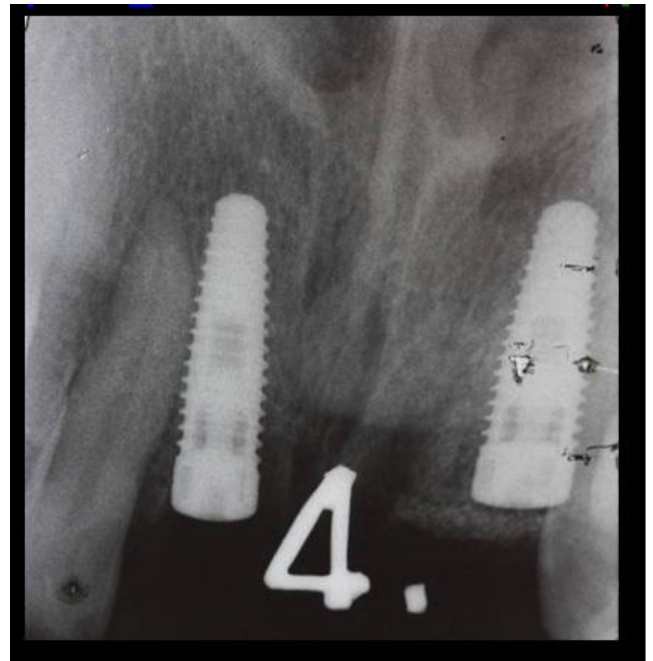

Figure 13: Peri-apical X-ray after first surgery

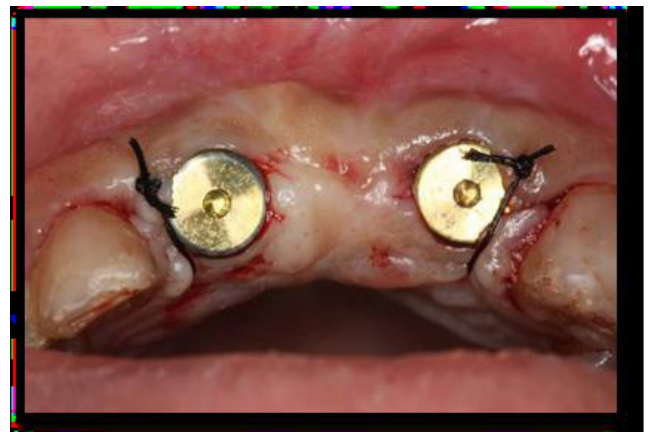

Figure 14: Healing abutment after second surgery

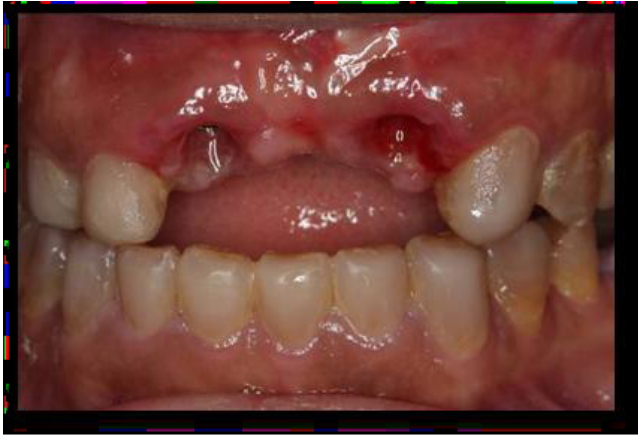

Figure 15: Gingival margin healing

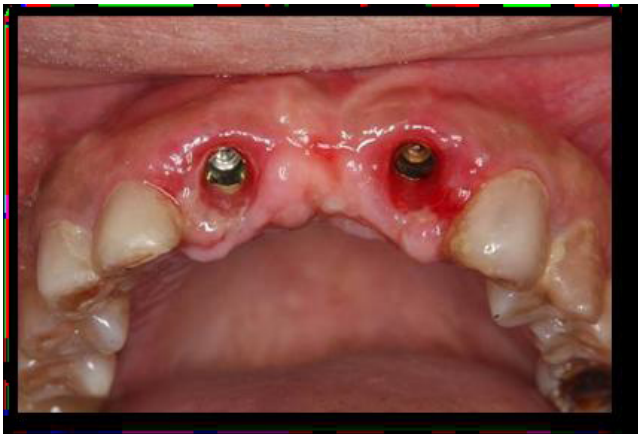

Figure 16: Occlusal view of gingival margin healing

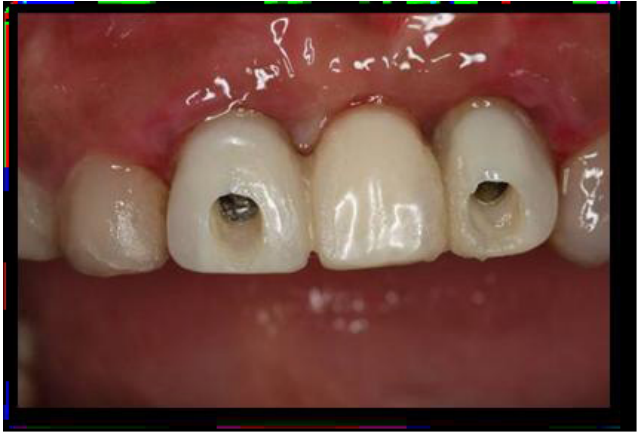

Figure 17: Screw Retained temporary bridge

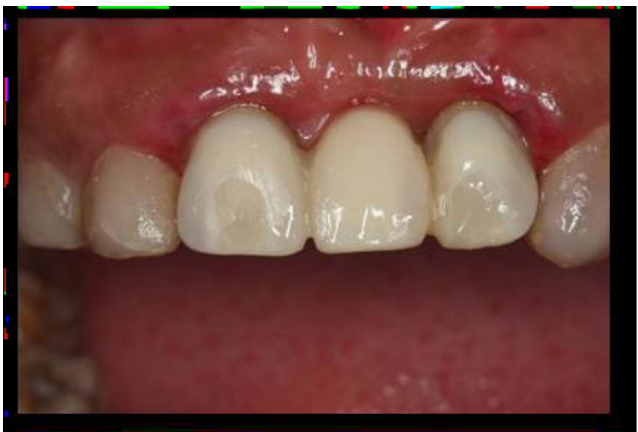

Figure 18: Closing access opening for screw retained temporary bridge (composite resin)

of nonfunctional acrylic resin provisional bridge in form of screw retained (Figures 14,15,16,17&18).

Step 6. Impression for the master cast

After 4 weeks , the soft tissue healed perfectly. Removed the provisional bridge, and took impressions directly with poly-ether material for the working cast (Figure 19).

Step 7. Try-in and cementation

The occlusal contacts should be checked with occlusal indicator papers before and after cementation. Finally, the metal ceramic bridge was cemented with glass ionomer cement (GIC) (Figure 20).

Then a radiograph was taken to verify seating of the restoration and acted as a record of alveolar bone status for comparison (Figure 21).

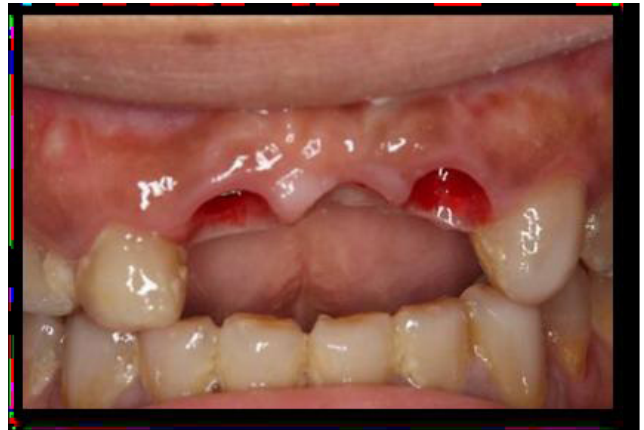

Figure 19: Gingival margin before final restoration

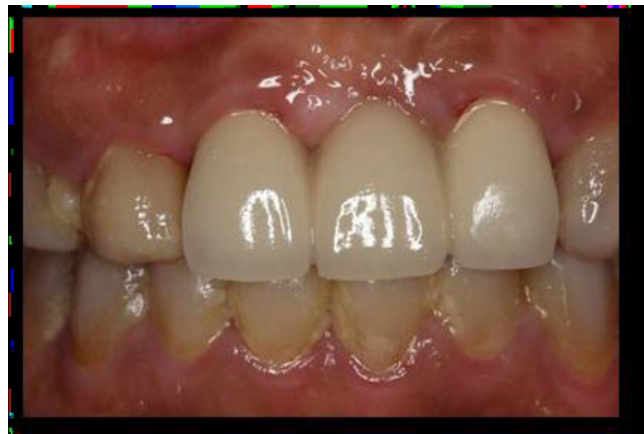

Figure 20: Labial view of the final restoration

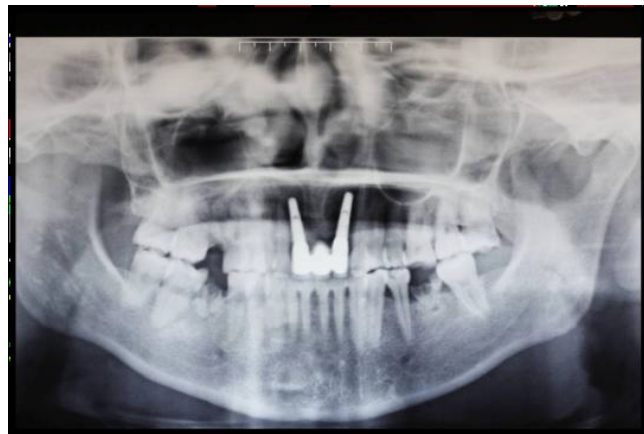

Figure 21: Panoramic X-ray of final treatment

Step 8. Periodic recall

The patient was informed some knowledge about maintain the oral hygiene and using of the implant restoration. Recall the patient periodically. The patient was evaluated clinically and radiographically at 1 week, 1 months, 3 months, 6 months, and one year. The examinations should include mobility of implant, soundness and integrity of provisional crowns, periodontal status, and marginal bone resorption and so on.

Discussion and conclusion

Endosseous dental implants are a predictable modality of tooth replacement that can improve the dental health and quality of life for many people.

Different study conducted by many researches has reported that, the success and survival rate of dental implant placed in anterior maxilla are almost same to other segment of jaw [12]. However, there is often inadequate bone to receive and support implants. This can be the result of trauma, periodontal disease, endodontic infection, post-extraction ridge defects, disuse atrophy, etc. [13].

Successful implant placement in planed site required enough bone volume of sufficient density to enable an implant of the appropriate size to be placed in a desirable position and orientation.

Placement of bone grafts in conjunction with endosseous dental implant shortens the treatment time without influencing the success rate or increase the complication [14].

The interaction between the graft and the surrounding host bone is very important and is the subject of much research [15].

The degree of bone grafting required for implant placement varies from localized deficiencies to cases where there is a need to change the entire arch form and/or jaw relationship.

Augmentation to create enough bone volume is done using either (GBR) Guided bone regeneration [15,16], autogenous bone grafts, including onlay grafts [17,18] and interpositional bone grafts [19], and combinations of these procedures. These grafting materials can be used in different clinical situation which can be summarized and following [20-23]:

- Regeneration of periodontal bone and furcation defects.
- Osseous defect regeneration.
- Regeneration of extraction sockets.
- Regeneration of gaps around block grafts.
- Horizontal alveolar crest augmentation.
- Sinus augmentation.

Using guide bone regeneration in construction of bone defects in predictable methods for regeneration of adequate bone volume for proper placement of dental implant. These can be simultaneously with implant placemat or staged approach [24]. Using of particular dental implant of specific body design and surface characteristic will influence the treatment success [25]. Tapered dental implant which mimicking the shape of natural root will have high initial stability [26]. The surface of dental implant using here is TiUnite surface, which enhanced osse-

ointegration and anchorage in surrounding bone. In the long term, it maintains marginal bone and soft tissue levels, maximizing functional endurance and esthetics [27-29].

Here a grafting with particulated hydroxyapatite bone graft to cover implant threaded exposed and to establish good labial bone contour to improve esthetic.

Another pre-requesting of this case to achieve optimal result is soft tissue management. Successful dental implant restoration in issue framing esthetic zone required a healthy and correctly contoured soft tissue framing, which is defined as the gingival contour that surrounds the prosthesis [30,31]. Preservation of interdental papilla and gingival margin which is symmetrical with gingival architecture of adjacent gingival [32,33]. Achieving aesthetics interdental papilla which is completely fill the space between teeth or implants required interproximal bone crest of 5 mm. of estimated contact point in planned restoration [34,35].

Three dimensional position of implant required to achieve optimal emergence profile [36]. Mesiodistally positioning of implant required 1.5 mm space between implant and adjacent teeth or between implant / implant [32,36].

Labio-Palatal positioning is also important, too far labial result in overcontouring of the crown and can cause recession due to decrease thickness of buccal bone [35]. While palatal positioning produce ridge lap which limiting the type of design and increasing the difficulty for maintenance [37-39]. The third position is apicoronal positioning, which if the implant is too far apically positioning they will be bone resorption and gingival recession. On other hand if there is coronal placement the esthetics may be compromise due to visibility of implant shoulder [40]. The implant should be placed 1.5 mm to 3.0 mm below the CEJ for optimal implant esthetics [41].

Tissue training help to develop a proper emergence profile and natural tooth appearance, help in re-establish normal gingival tissue contours and interdental papillae [24]. Fabricating provisional restoration before inserting the final prosthesis which will improve esthetics.

References

- 1) Zarb GA, Bolender CL, Eckert ST, Jacob RF, Fenton AH, et al. (2004) *Prosthodontic Treatment for Edentulous Patients*. Charles L Bolender (eds) *The edentulous predicament* (12th edn), CV Mosby & CO, St Louis.
- 2) World health organization (2012) *Oral health. fact sheet No 318*.
- 3) Cantore S, Ballini A, Crincoli V, Grassi FR (2009) Treatment of horizontal root fracture: a case report. *Cases J* 2: 8101.
- 4) Palmer RM, Palmer PJ, Newton JT (2003) Dealing with esthetic demands in the anterior maxilla. *Periodontol* 33:105-118.
- 5) Cawood JI, Howell RA (1991) Reconstructive prosthetics surgery: I. Anatomical considerations. *Int J Oral Maxillofacial Surg* 20:75-82.
- 6) Podovan LEM, Sartori IAM, Thome G, Melo ACM (2008) Immediate load implants and osteointerados: SaoPaulo, Santos (eds) *Possibilidades and techics* (1stedn).
- 7) Listgarten MA, Lang NP, Schroeder HE, Schroeder A (1991) Periodontal tissues and their counterparts around endosseous implants. *Clin Oral Implants Res* 2: 1-19.

- 8) Khoury F (1987) The modified alveolar Extensions plastic with Zahnrlrz Implant.
- 9) Lustmann J, Lewinstein I (1995) Interpositional bone grafting technique to widen narrow maxillary ridge. *Int J Oral Maxillofac Implants* 10: 568-577.
- 10) Misch CM, Misch CE, Resnik RR, Ismail YH (1992) Reconstruction of maxillary alveolar defects with mandibular symphysis grafts for dental implants: a preliminary procedural report. *Int J Oral Maxillofac Implants* 7: 360-366.
- 11) Hammerle CH, Jung RE (2008) *Clinical Periodontology and Implant Dentistry (Vol.2)*. J Lindhe, NP Lang, T Karring (eds) Ridge augmentation procedures (5th edn) Blackwell Publication, Munksgaard.
- 12) Belser UC, Schmid B, Higginbottom F, Buser D (2004) Outcome analysis of implant restorations located in the anterior maxilla: a review of the recent literature. *Int J Oral Maxillofac Implants* 19: 30-42.
- 13) Kahnberg K-E (2005) *Bone Grafting Techniques for Maxillary Implants*. Kahnberg K-E, Rasmusson L, Zellin G (eds) *Bone Grafting Techniques for Maxillary Implants* (1st edn) Blackwell Publishing Co., Munksgaard.
- 14) Boronat A, Carrillo C, Penarrocha M, Penarrocha M (2010) Dental implants placed simultaneously with bone grafts in horizontal defects: a clinical retrospective study with 37 patients. *Int J Oral Maxillofac Implants* 25: 189-196.
- 15) Buser D, Dula K, Belser UC, Hirt HP, Berthold H (1995) Localized ridge augmentation using guided bone regeneration. II. Surgical procedure in the mandible. *Int J Periodontics Restorative Dent* 15: 10-29.
- 16) Schwarz F, Sahm N, Becker J (2012) Impact of the outcome of guided bone regeneration in dehiscence-type defects on the long-term stability of peri-implant health: clinical observations at 4 years. *Clin Oral Implants Res* 23: 191-196.
- 17) Misch CM, Misch CE (1995) The repair of localized severe ridge defects for implant placement using mandibular bone grafts. *Implant Dent* 4: 261-267.
- 18) Ten Bruggenkate CM, Kraaijenhagen HA, van der Kwast WA, Krekeler G, Oosterbeek HS (1992) Autogenous maxillary bone grafts in conjunction with placement of I.T.I. endosseous implants. A preliminary report. *Int J Oral Maxillofac Surg* 21: 81-84.
- 19) Esposito M, Grusovin MG, Kwan S, Worthington HV, Coulthard P (2008) Interventions for replacing missing teeth: bone augmentation techniques for dental implant treatment. *Cochrane Database Syst Rev* : CD003607.
- 20) Dayi E, Aslan M, Simşek G, Yilmaz AB (2002) The effects of bone chips dehydrated with solvent on healing bone defects. *J Int Med Res* 30: 168-173.
- 21) Noubissi SS, Lozada JL, Boyne PJ, Rohrer MD, Clem D, et al. (2005) Clinical, histologic, and histomorphometric evaluation of mineralized solvent-dehydrated bone allograft (Puros) in human maxillary sinus grafts. *J Oral Implantol* 31: 171-179.
- 22) Block MS, Degen M (2004) Horizontal ridge augmentation using human mineralized particulate bone: preliminary results. *J Oral Maxillofac Surg* 62: 67-72.
- 23) Le B, Burstein J, Sedghizadeh PP (2008) Cortical tenting grafting technique in the severely atrophic alveolar ridge for implant site preparation. *Implant Dent* 17: 40-50.
- 24) Morley S, Rubinoff, DDS, Cert Prosth (2003) Single-Tooth Implant Reconstruction in the Anterior Maxilla. *Journal of the Canadian Dental Association* 69: 10-24.
- 25) Leonhardt A, Gröndahl K, Bergström C, Lekholm U (2002) Long-term follow-up of osseointegrated titanium implants using clinical, radiographic and microbiological parameters. *Clin Oral Implants Res* 13: 127-132.
- 26) Buser D, Martin W, Belser UC (2004) Optimizing esthetics for implant restorations in the anterior maxilla: anatomic and surgical considerations. *Int J Oral Maxillofac Implants* 19: 43-61.
- 27) Zechner W, Tangl S, Fürst G, Tepper G, Thams U (2003) Osseous healing characteristics of three different implant types. *Clin Oral Implants Res* 14: 150-157.
- 28) Östman PO, Hellman M, Sennerby L (2012) Ten years later. Results from a prospective single-centre clinical study on 121 oxidized (TiUnite™) Brånemark implants in 46 patients. *Clin Implant Dent Relat Res* 14: 852-860.
- 29) Glauser R (2012) Eleven-year results of implants with an oxidized surface placed predominantly in soft bone and subjected to immediate occlusal loading. *Clin Oral Impl Res* 23: 140-141.
- 30) Davidoff SR (1996) Developing soft tissue contours for implant-supported restorations: a simplified method for enhanced aesthetics. *Pract Periodontics Aesthet Dent* 8: 507-513.
- 31) Kan JY, Morimoto T, Rungcharassaeng K, Roe P, Smith DH (2010) Gingival biotype assessment in the esthetic zone: visual versus direct measurement. *Int J Periodontics Restorative Dent* 30: 237-243.
- 32) Garber DA, Salama MA, Salama H (2001) Immediate total tooth replacement. *Compend Contin Educ Dent* 22: 210-218.
- 33) Paolantoni G, Marenzi G, Fusco A, Sammartino G (2007) Implant rehabilitation of central incisor: a staged approach. *Implant Dent* 16: 349-355.
- 34) Tarnow D, Elian N, Fletcher P, Froum S, Magner A, et al. (2003) Vertical distance from the crest of bone to the height of the interproximal papilla between adjacent implants. *J Periodontol* 74: 1785-1788.
- 35) Elian N, Bloom M, Dard M, Cho SC, Trushkowsky RD, et al. (2011) Effect of interimplant distance (2 and 3 mm) on the height of interimplant bone crest: a histomorphometric evaluation. *J Periodontol* 82: 1749-1756.
- 36) Buser D, Martin W, Belser UC (2004) Optimizing esthetics for implant restorations in the anterior maxilla: anatomic and surgical considerations. *Int J Oral Maxillofac Implants* 19: 43-61.
- 37) Belser UC, Bernard JP, Buser D (1996) Implant-supported restorations in the anterior region: prosthetic considerations. *Pract Periodontics Aesthet Dent* 8: 875-883.
- 38) Belser UC, Buser D, Hess D, Schmid B, Bernard JP, et al. (2000) Aesthetic implant restorations in partially edentulous patients--a critical appraisal. *Periodontol* 2000 : 132-150.
- 39) Tarnow DP, Eskow RN (1995) Considerations for single-unit esthetic implant restorations. *Compend Contin Educ Dent* 16: 778,780,782-784.
- 40) Bashutski JD, Wang HL (2007) Common implant esthetic complications. *Implant Dent* 16: 340-348.
- 41) Zetu L, Wang HL (2005) Management of inter-dental/inter-implant papilla. *J Clin Periodontol* 32: 831-839.

**Submit your manuscript to a JScholar journal
and benefit from:**

- ¶ Convenient online submission
- ¶ Rigorous peer review
- ¶ Immediate publication on acceptance
- ¶ Open access: articles freely available online
- ¶ High visibility within the field
- ¶ Better discount for your subsequent articles

Submit your manuscript at
<http://www.jscholaronline.org/submit-manuscript.php>